

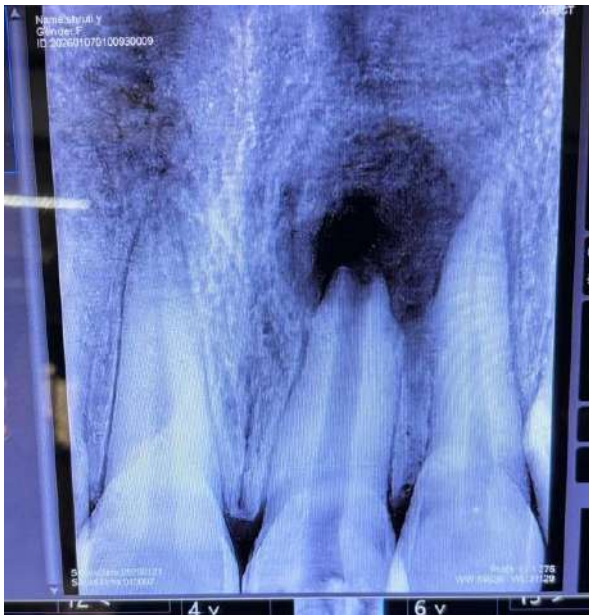**PEOPLES COLLEGE OF DENTAL
SCIENCES AND RESEARCH
CENTRE, BHOPAL**

**DEPARTMENT OF CONSERVATIVE
DENTISTRY AND ENDODONTICS**

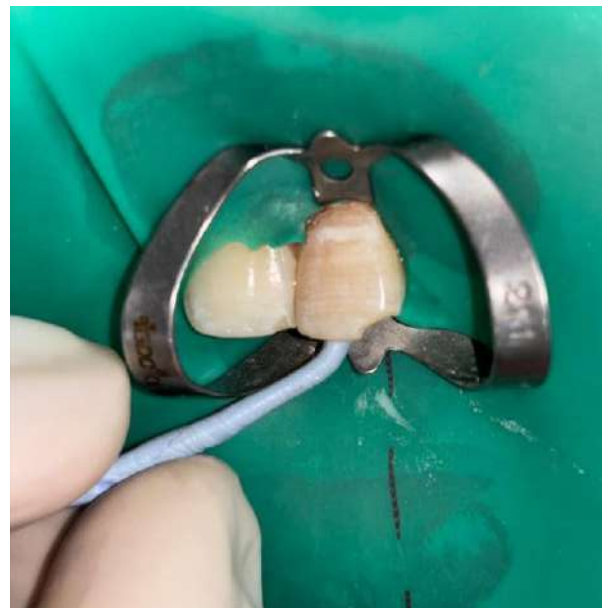SPECIAL CASES

APRIL 2025

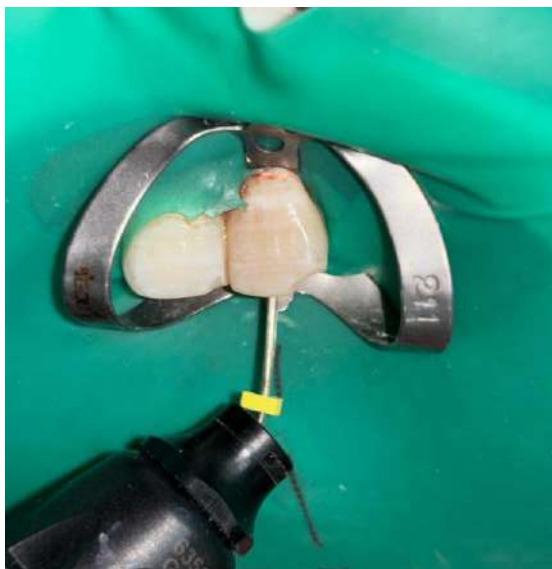CASE OF OPEN APEX [APEXIFICATION]



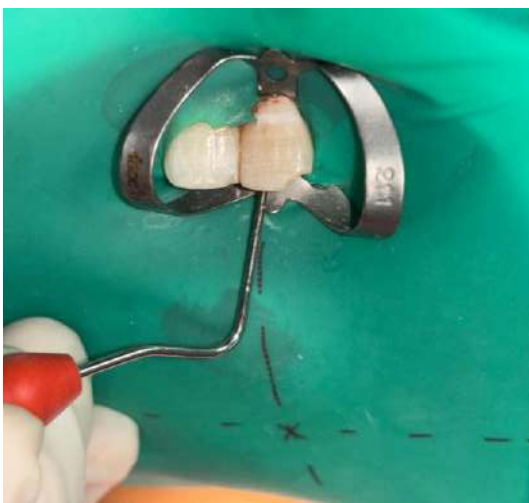
pre operative radiograph



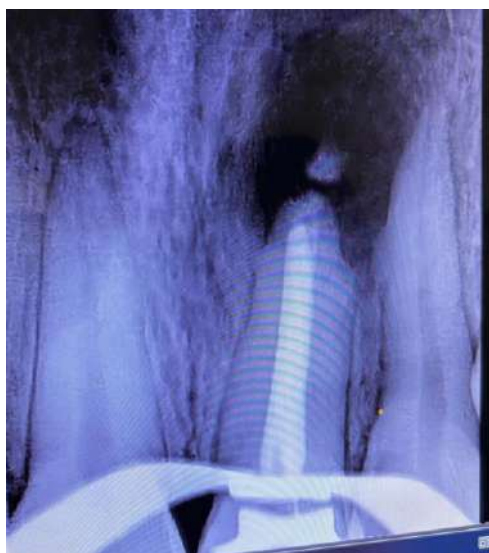
mta plug formation



thermoplasticised obturation

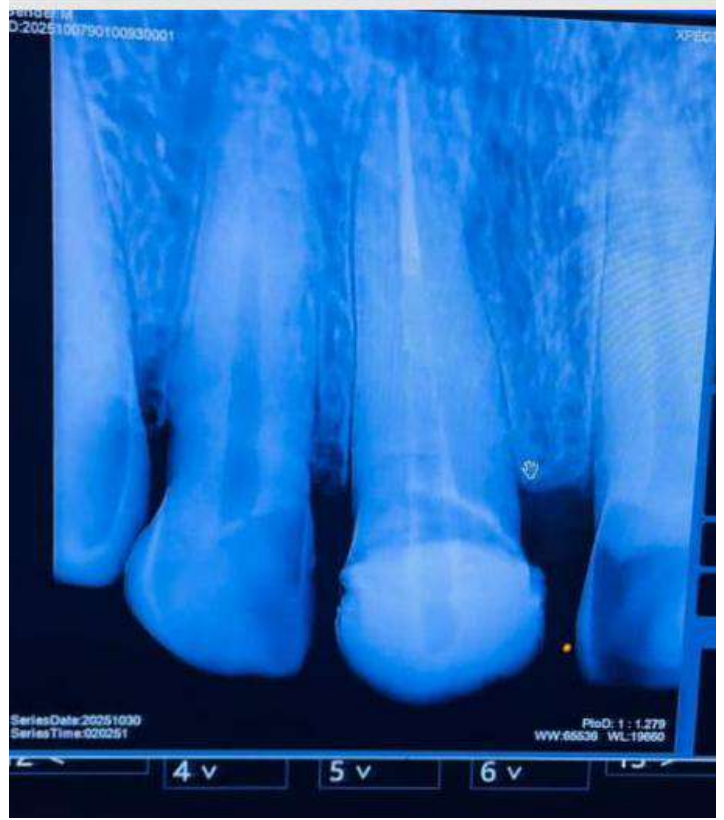
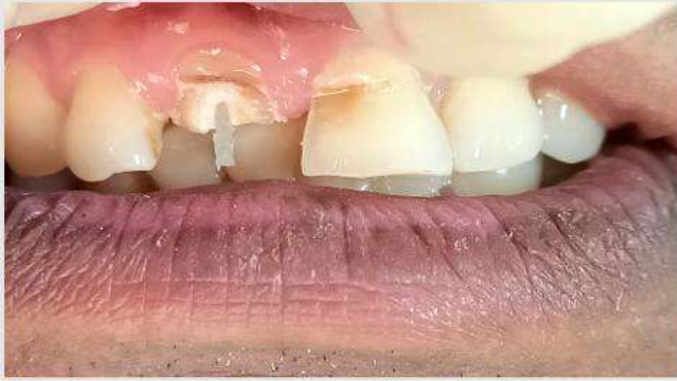
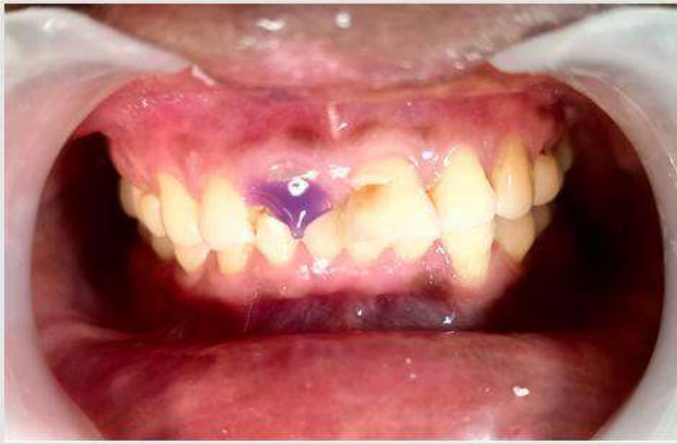
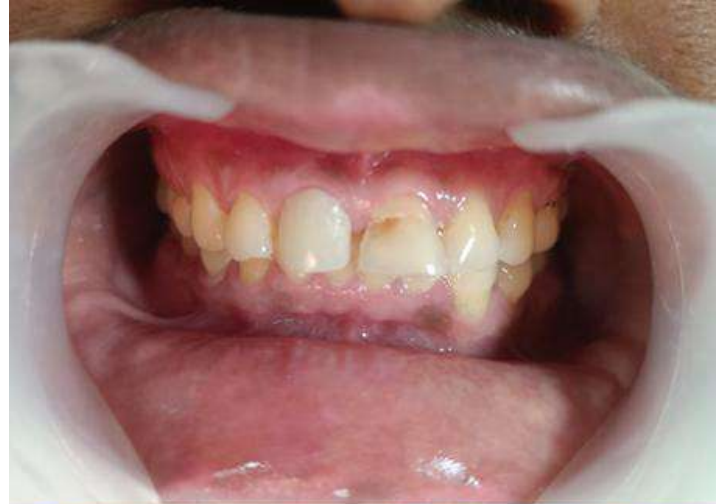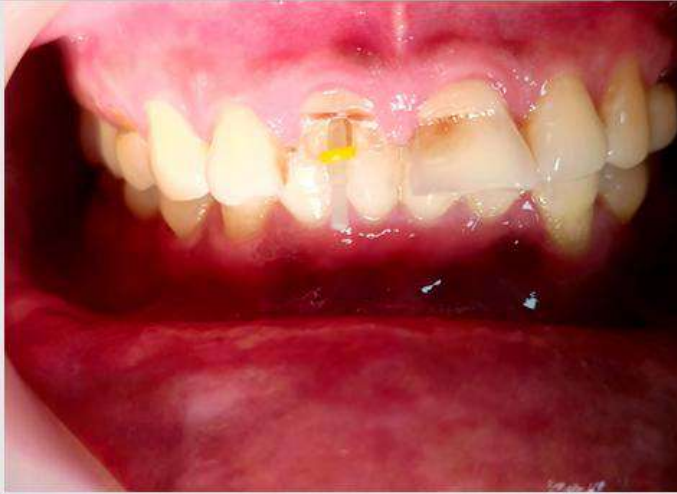compaction using plugger

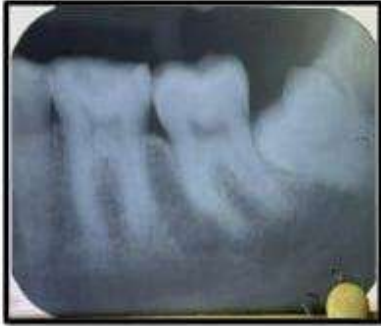

post operative radiograph

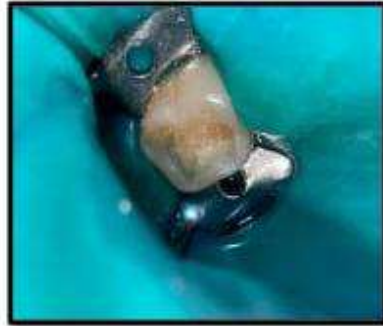ANTERIOR FIBRE POST AND CORE BUILDUP



CAST METAL INLAY



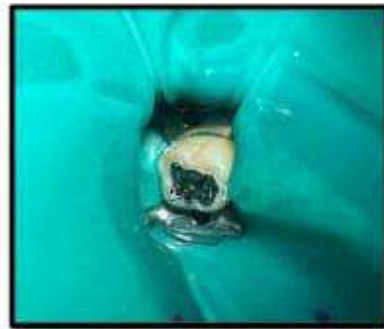PRE-OPERATIVE IOPAR



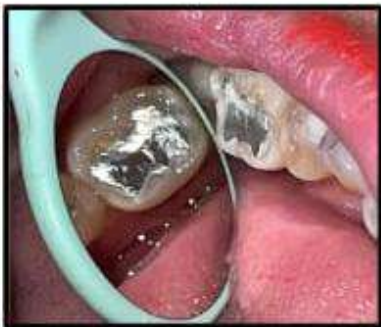CAVITY PREPARED



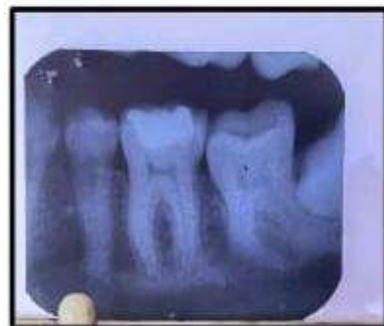METAL INLAY



INLAY CEMENTED



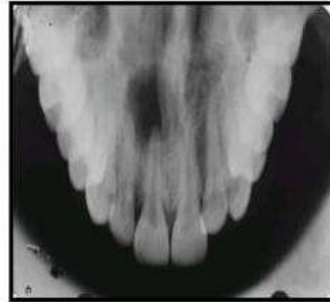
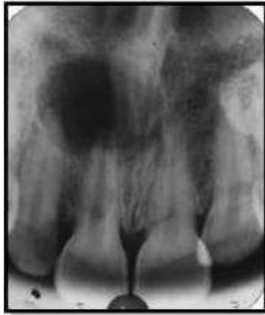
FINISHING AND POLISHING



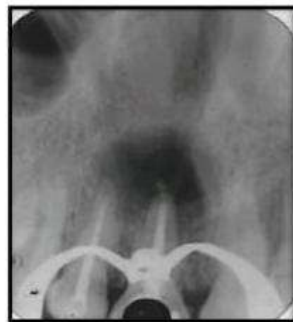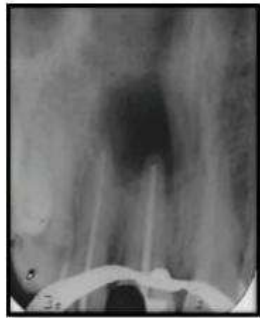POST-OPERATIVE IOPAR

MAY 2025

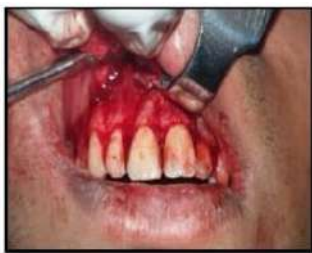PERIAPICAL SURGERY



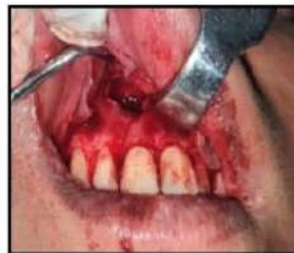Pre-Operative Radiographs



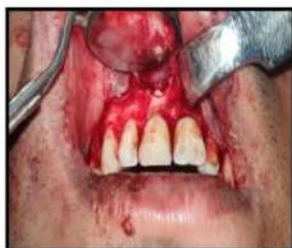Post-Obturation Radiograph



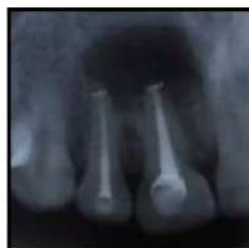Flap



Osteotomy Cut Given

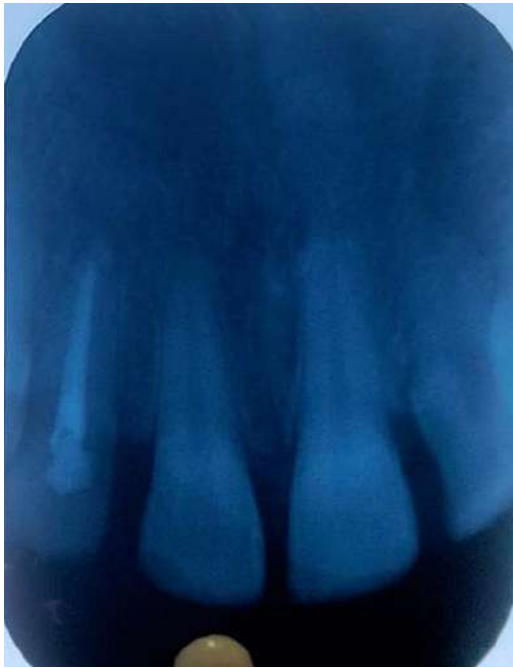

Retrograde

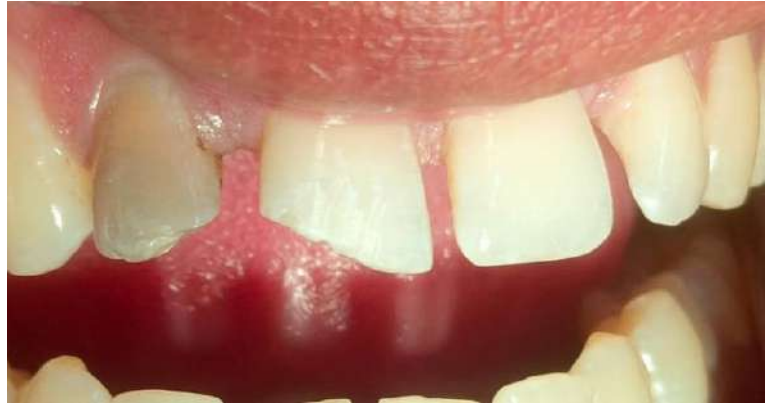

Post-Operative

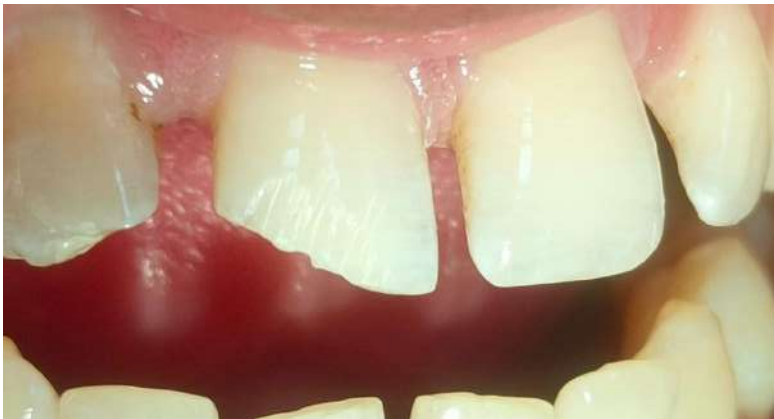COMPOSITE BUILDUP



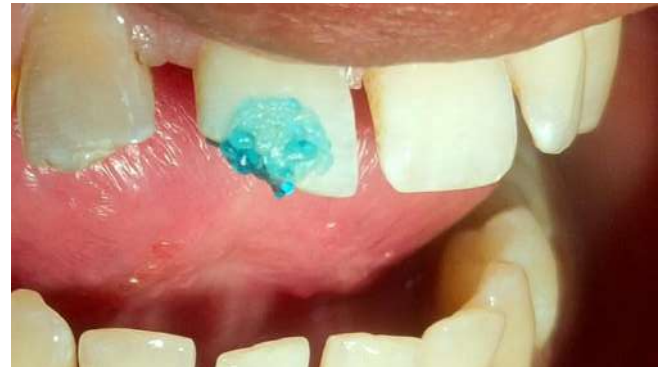Pre- operative Radiograph



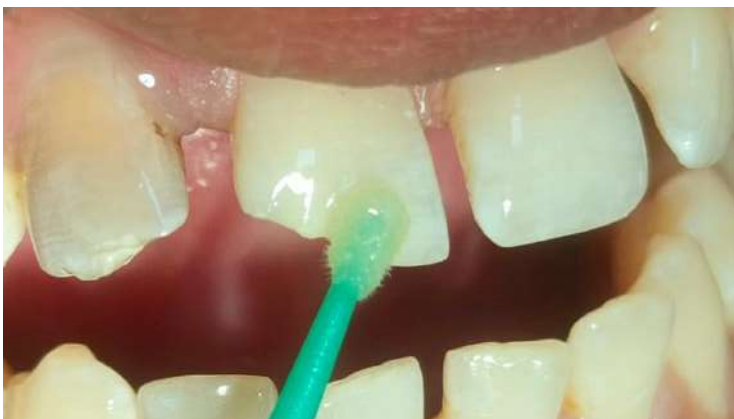Pre- operative



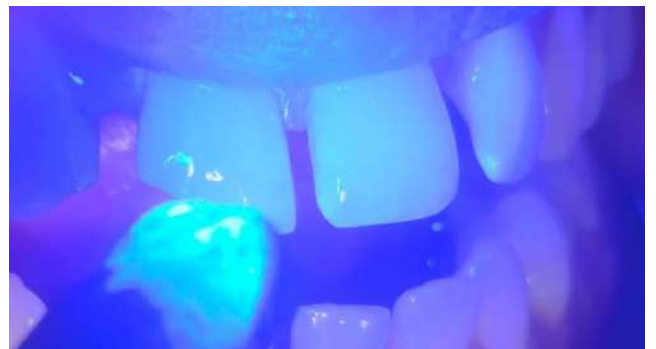Bevels Given on Enamel Surface



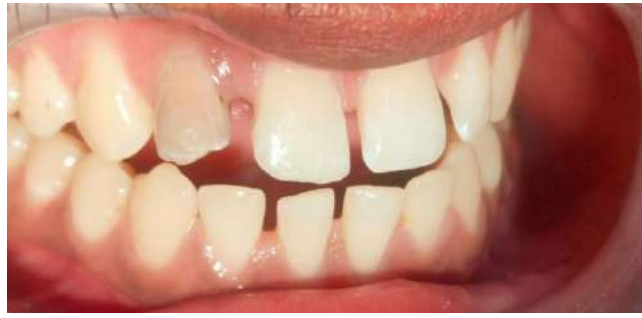Etchant Application done



Bonding Agent applied



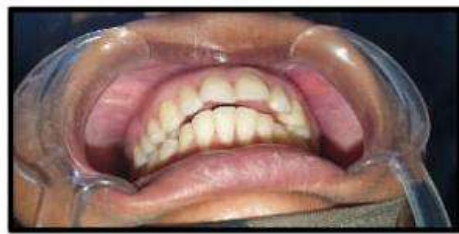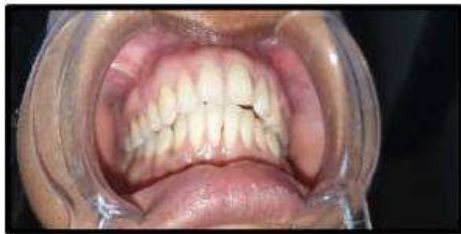Light Curing Done



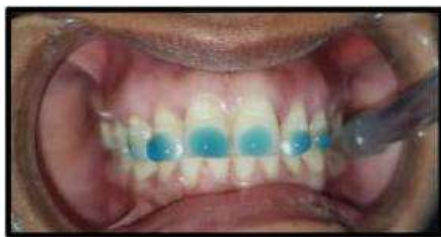Composite Buildup Done

JUNE 2025

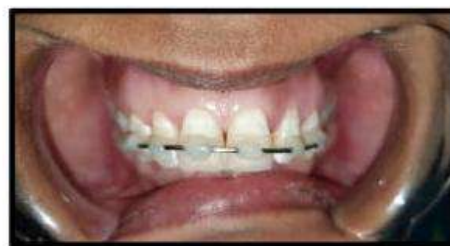Composite Splinting w.r.t 11,12



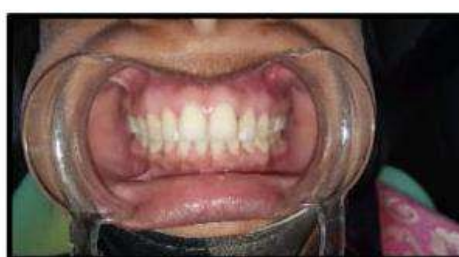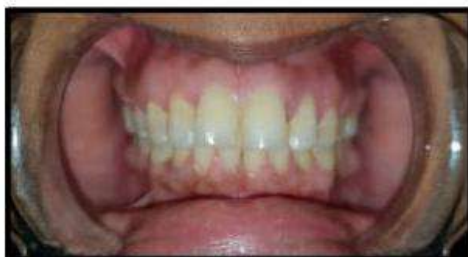Pre-Operative Photographs



Etching

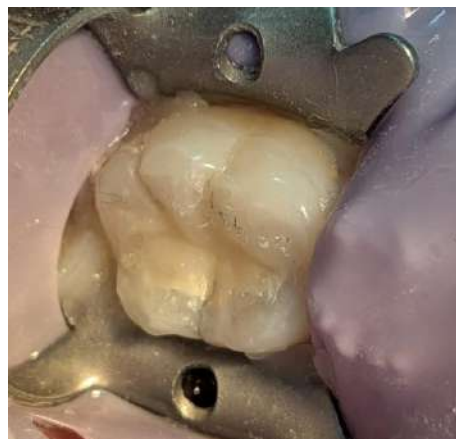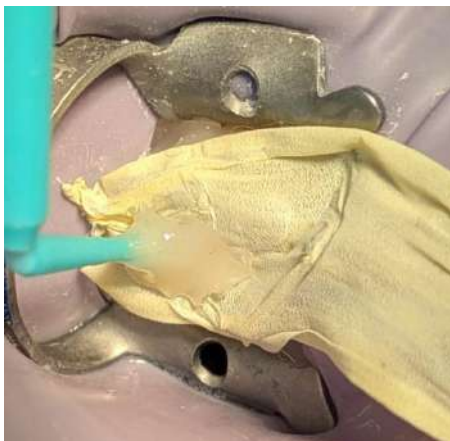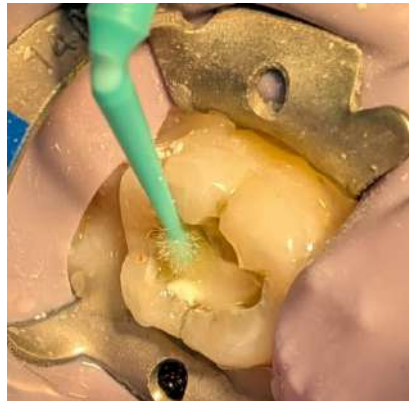
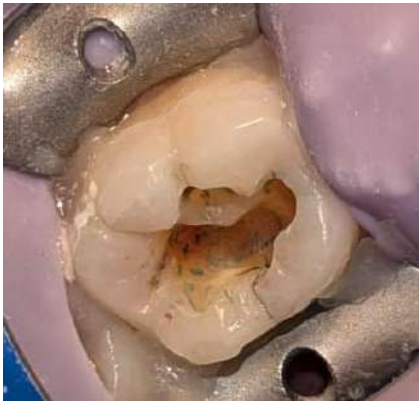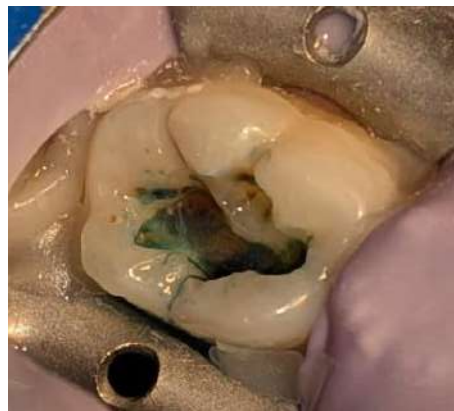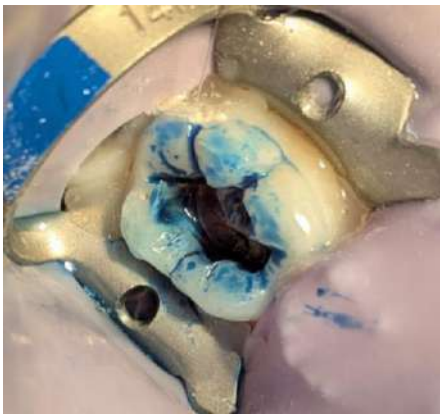
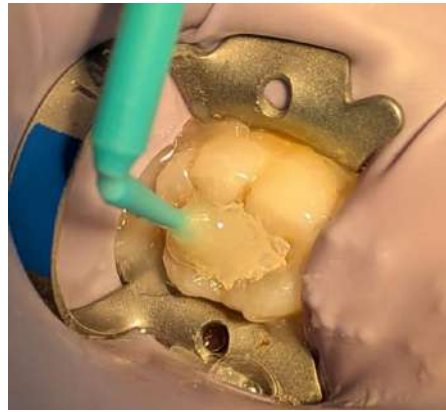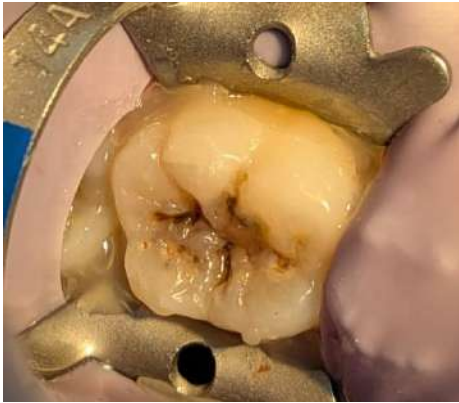


Splinting

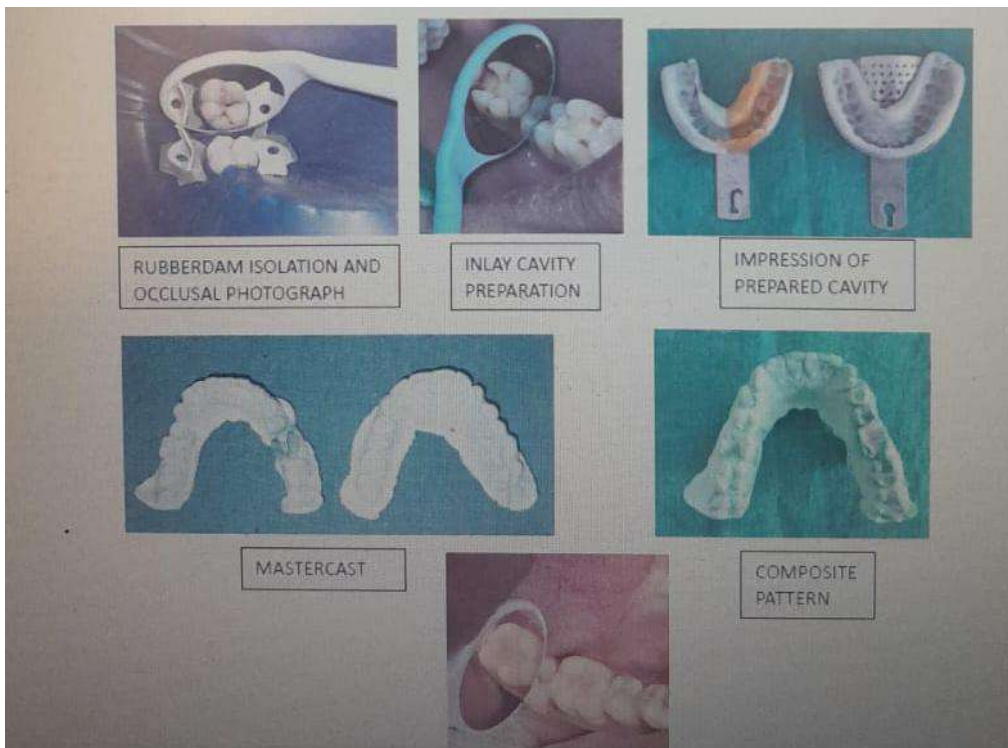
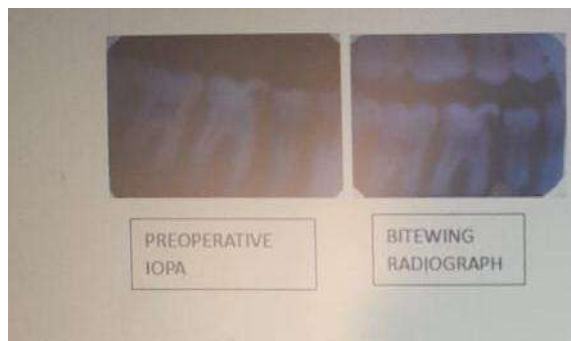
Post-Operative Photographs

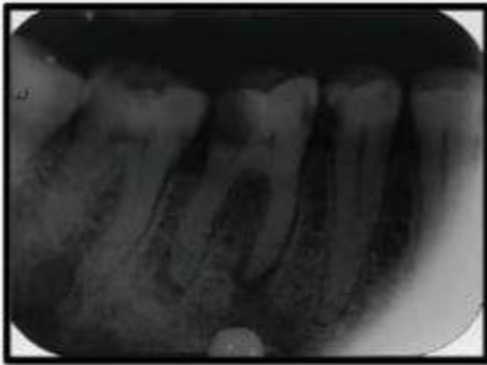
STAMP TECHNIQUE



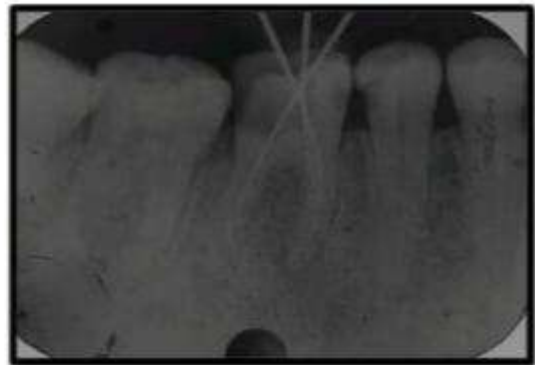COMPOSITE INLAY



Fiber Post w.r.t 46



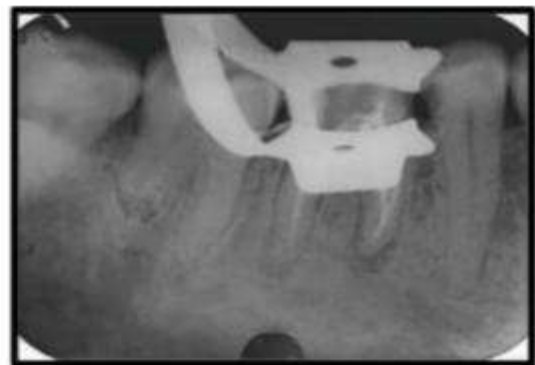PRE-OPERATIVE




WORKING LENGTH



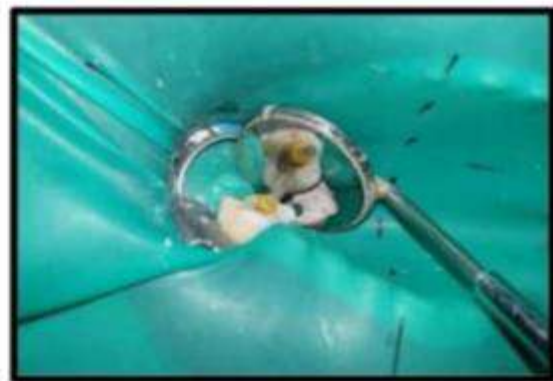
MASTER CONE IOPAR



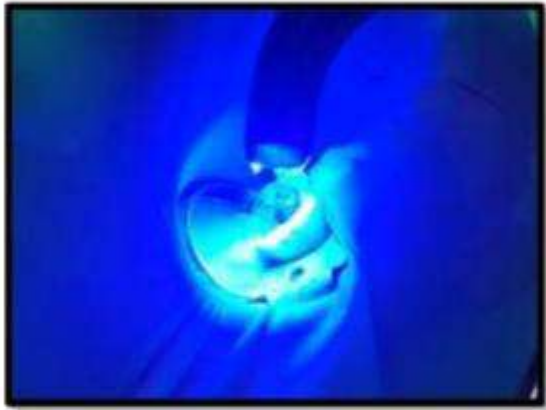
OBTURATION IOPAR



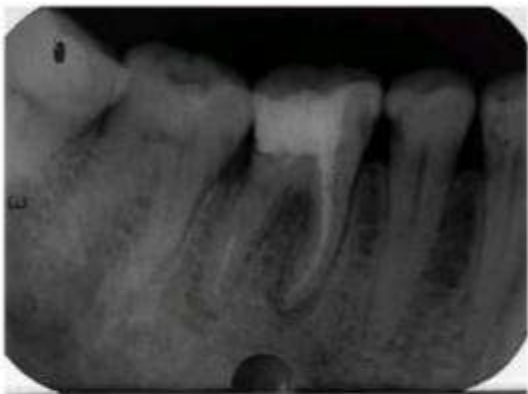FIBRE POST



FIBRE POST

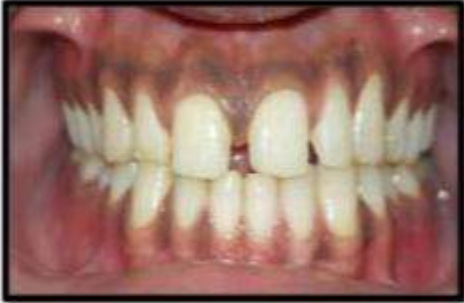

Curing done

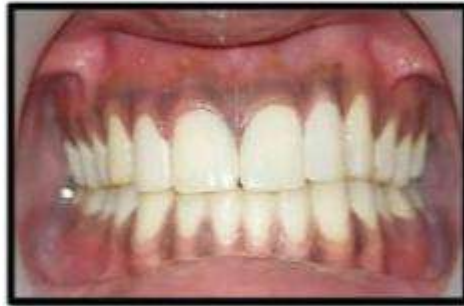

POST OPERATIVE IOPAR

Mid line Diastema Closure w.r.t 11,21



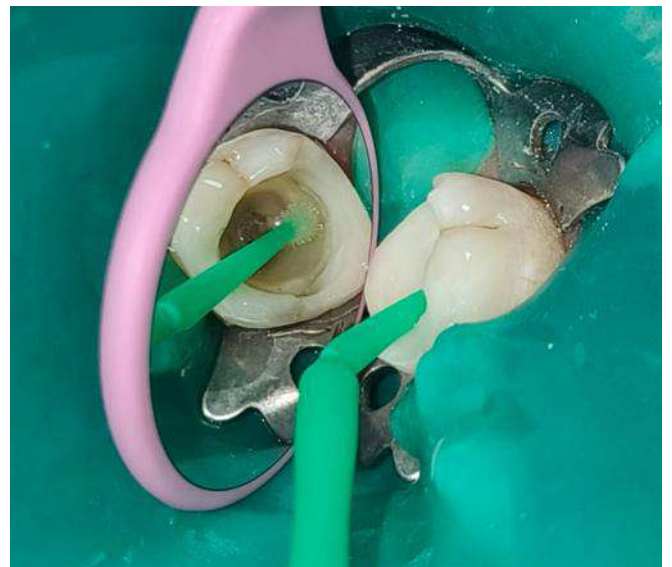
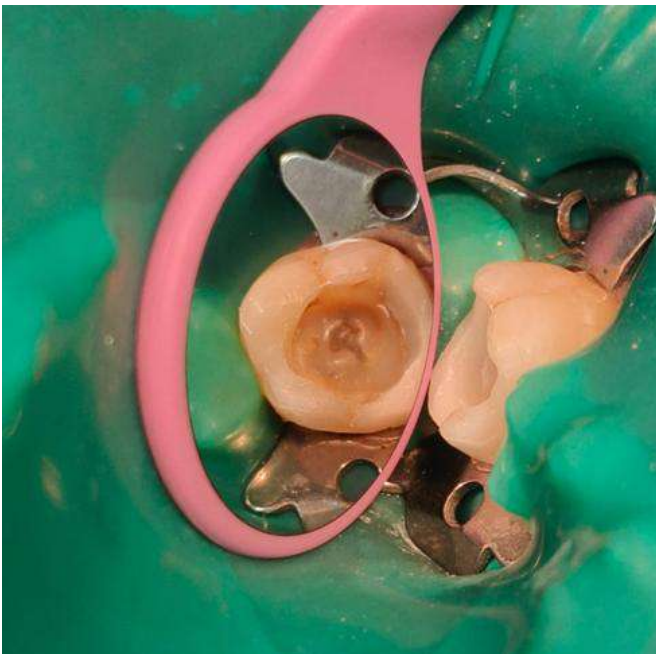
Pre- Operative Photograph

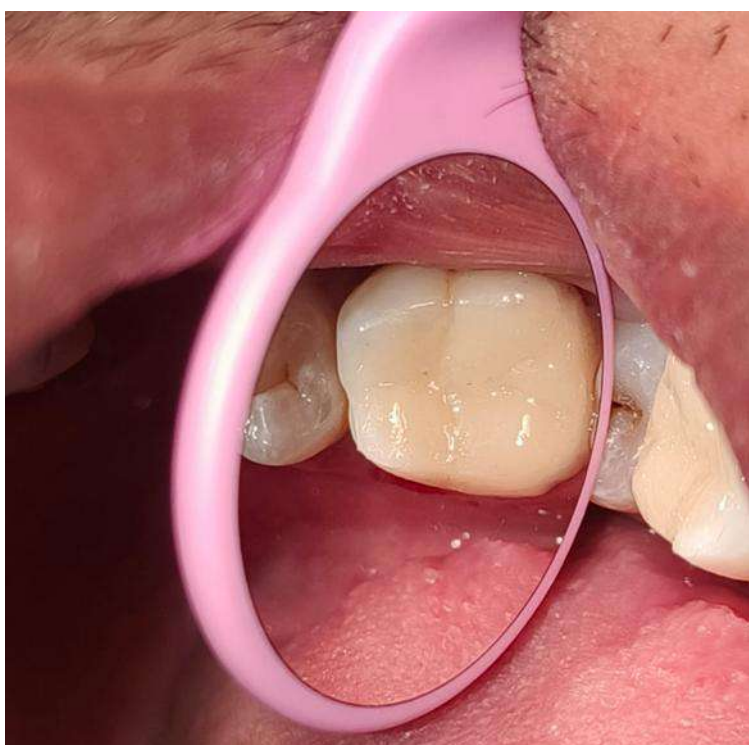
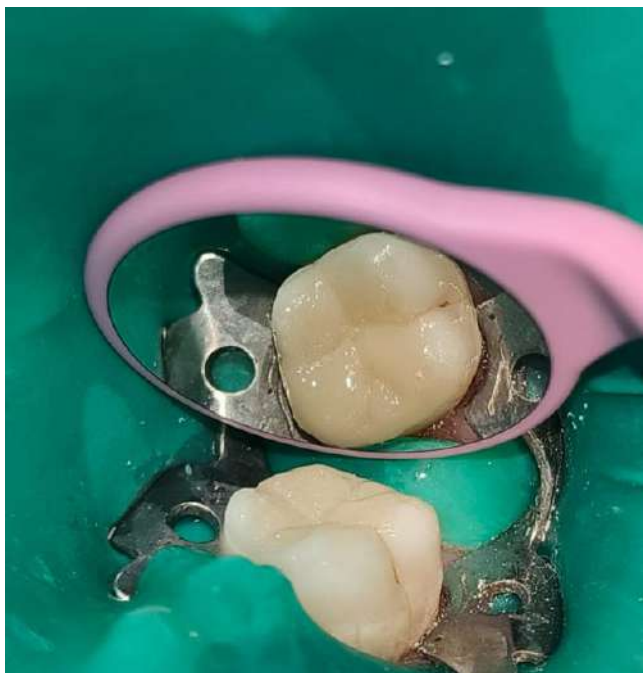
Post- Operative

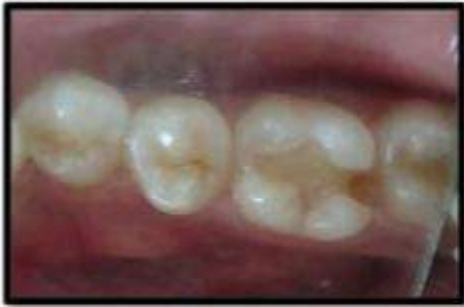AUGUST 2025

COMPOSITE RESTORATION

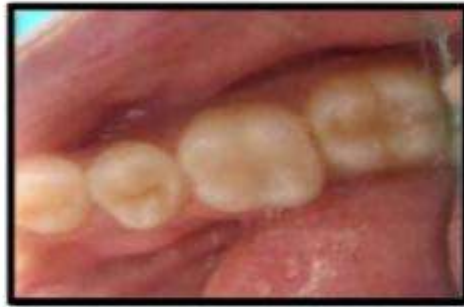



Class II composite restoration w.r.t 11,21

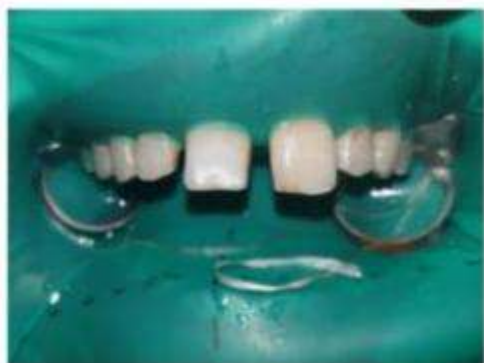

Pre- Operative Photograph



Post- Operative

SEPTEMBER 2025



PREOPERATIVE

NAME – ADARSH MISHRA

AGE – 23

CHIEF COMPLAINT –

patient complains of whitish discoloration in upper front tooth region since 5-6 years

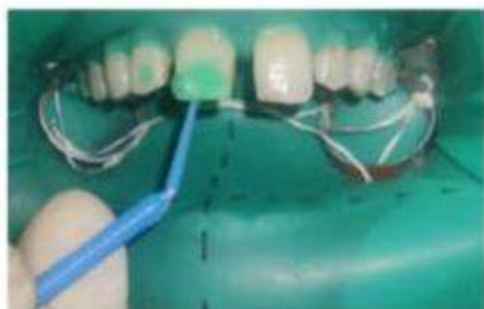PAST MEDICAL HISTORY – No relevant history

PAST DENTAL HISTORY – No relevant history

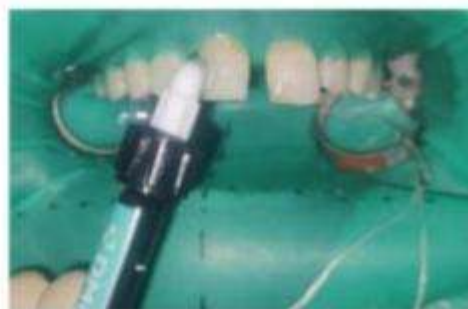HISTORY OF PRESENT ILLNESS – History of white discoloration since 5-6 years

PROVISIONAL DIAGNOSIS – White spot lesion

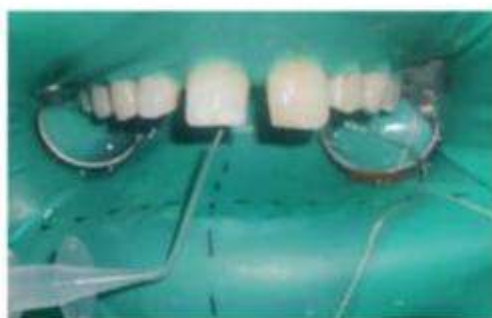TREATMENT PLAN – Resin infiltration by DGM icon



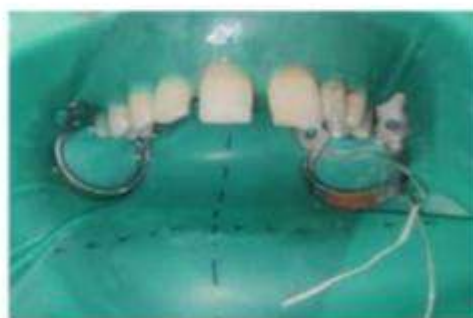APPLICATION OF GEL



APPLICATION OF DMG ICON



RESIN INFILTRATION

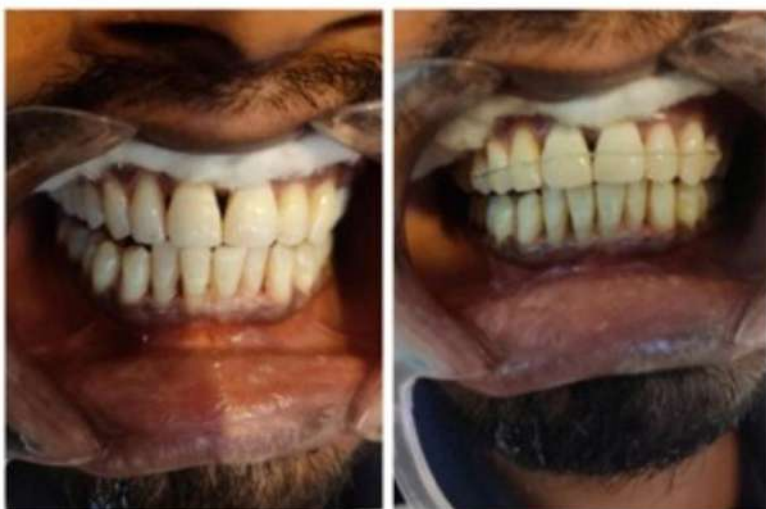
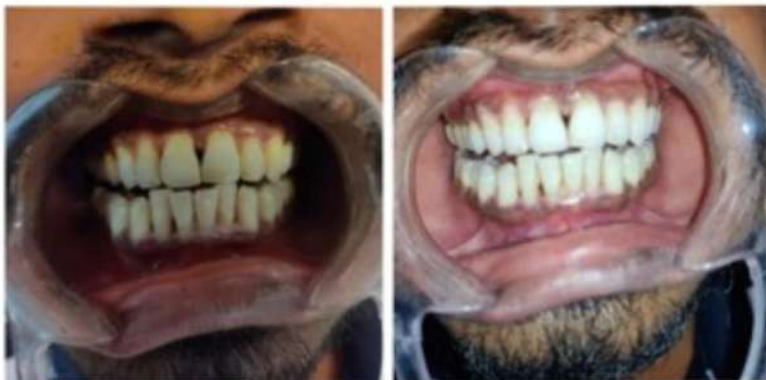
POST OPERATIVE RESULT

OCTOBER 2025

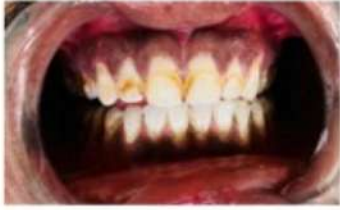Splinting Case

SPLINTING

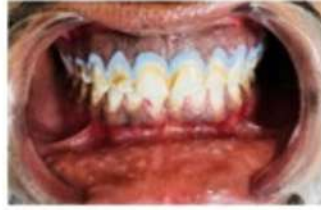

Vital Bleaching

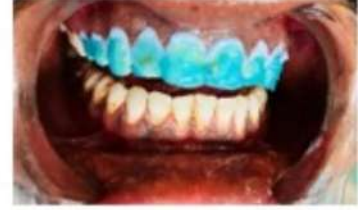Vital Bleaching



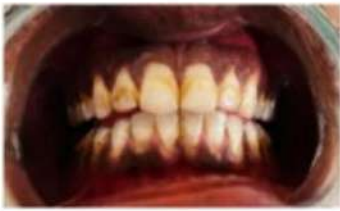Pre operative



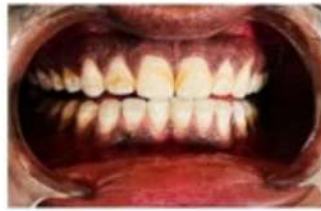Gingival barrier



Bleaching agent



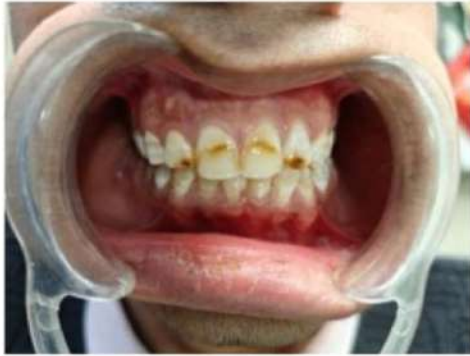1st visit



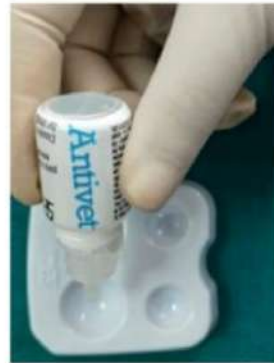2nd visit

In Office Vital Bleaching

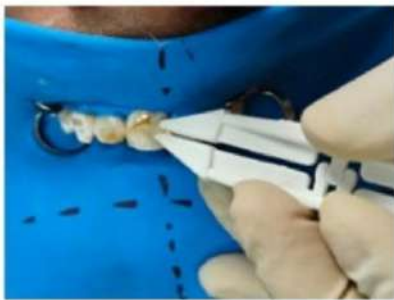IN OFFICE VITAL BLEACHING



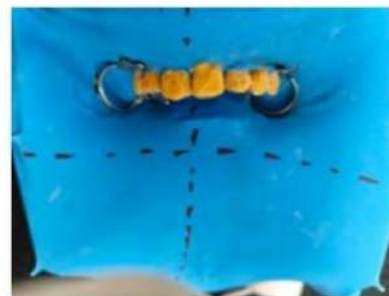PRE OPERATIVE



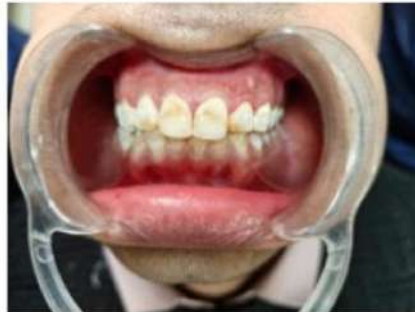DISPENSING OF BLEACHING AGENT



BLEACHING AGENT APPLICATION



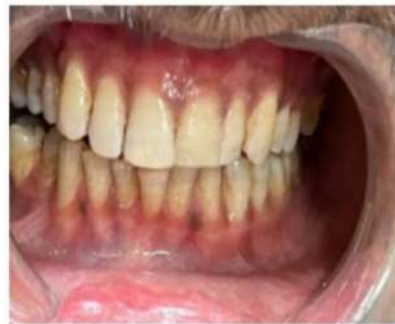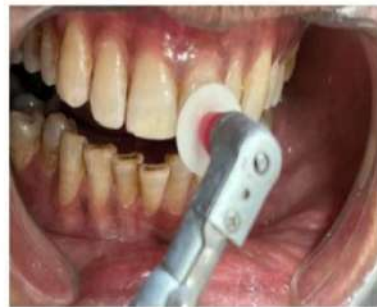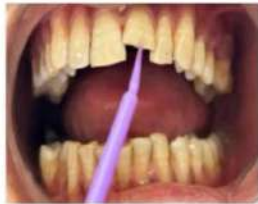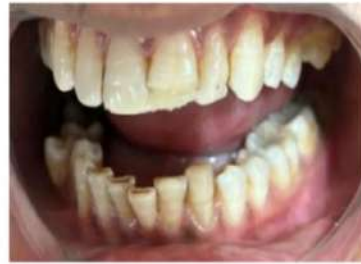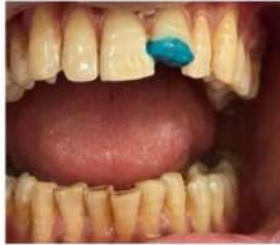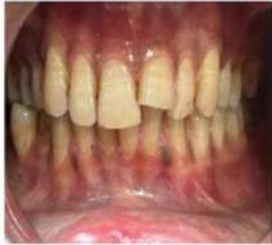PROPHYLAXIS PASTE APPLICATION



POST OPERATIVE

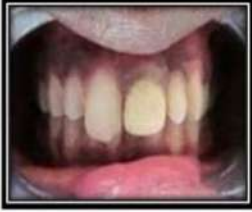NOVEMBER 2025

Composite Restoration

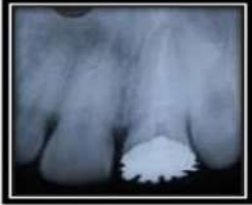

FIBER POST

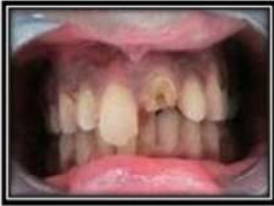AND CORE



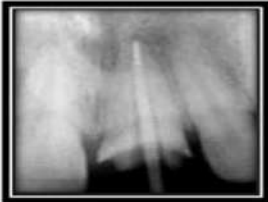PREOPERATIVE
PHOTOGRAPH



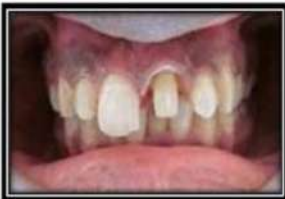POST SPACE
PREPARATION



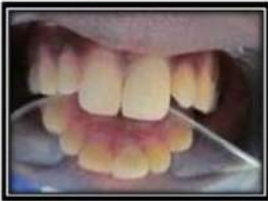PLACEMENT OF
FIBER POST



RADIOGRAPH
TAKEN



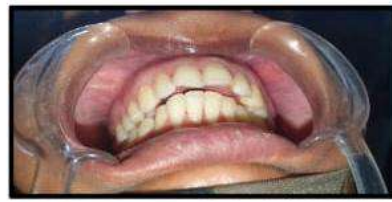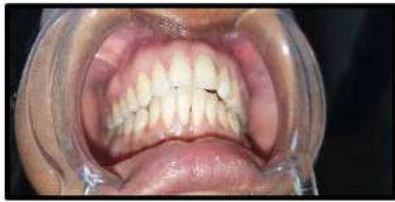COMPOSITE BUILDUP
DONE



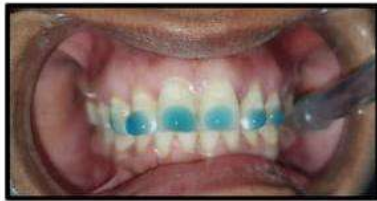POST OPERATIVE
CERAMIC CROWN
PLACEMENT

Composite splinting

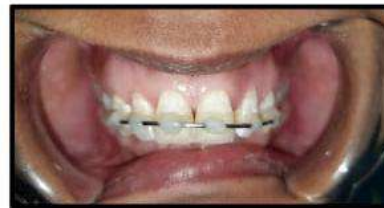Composite Splinting w.r.t 11,12



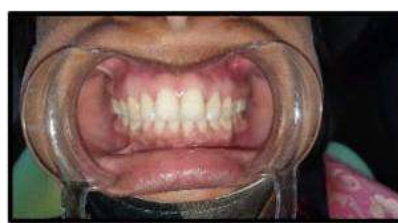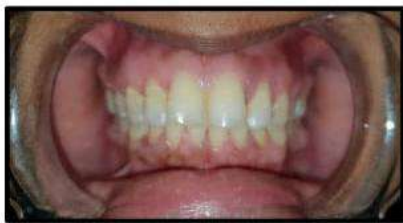Pre-Operative Photographs



Etching



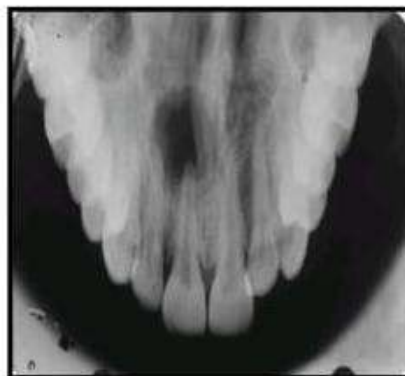
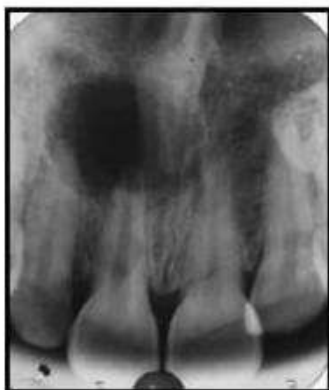
Splinting



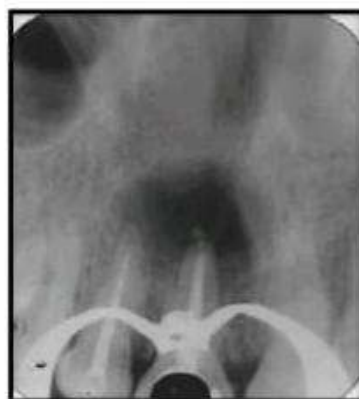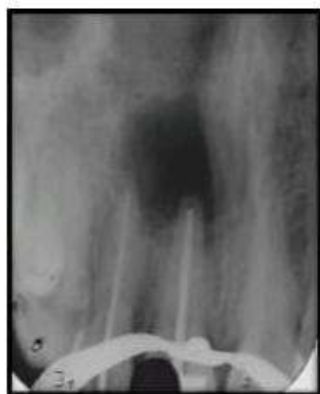Post-Operative Photographs

Periapical surgery

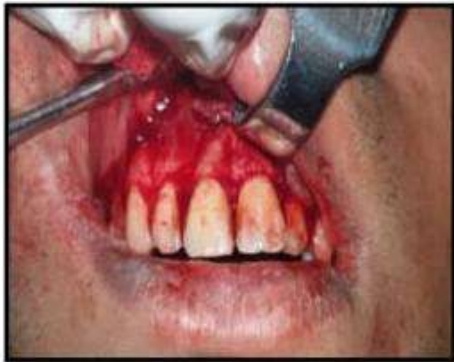Periapical Surgery w.r.t 11,21



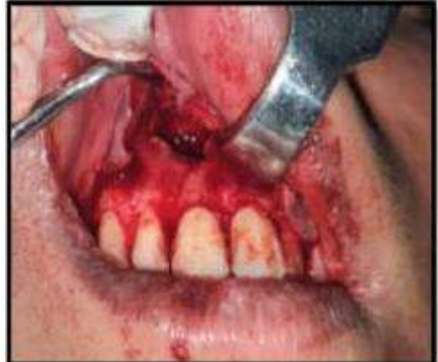Pre-Operative Radiographs



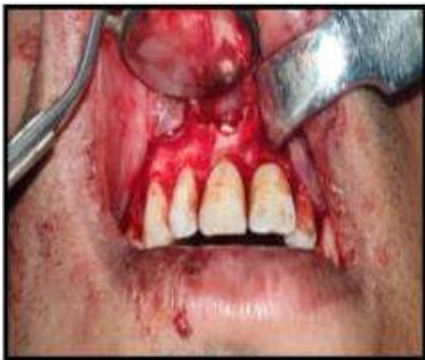Post-Obturation Radiograph



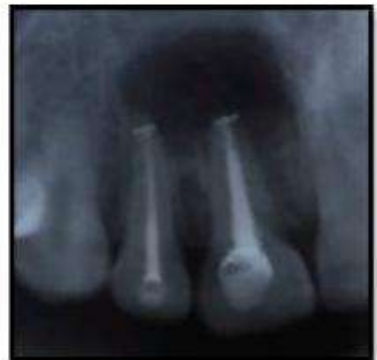Flap



Osteotomy Cut Given

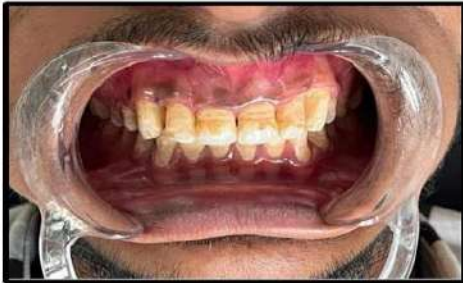

Retrograde

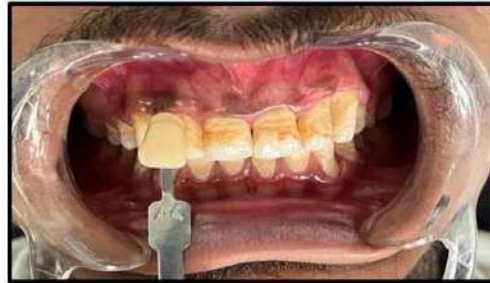

Post-Operative

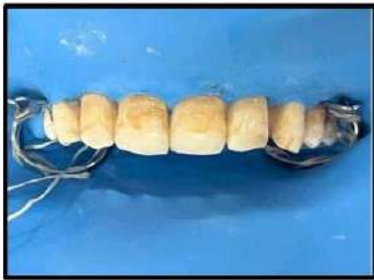Case 1: Inoffice Vital teeth bleaching using Antivet kit.



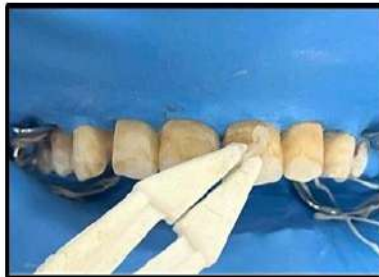Pre-Operative



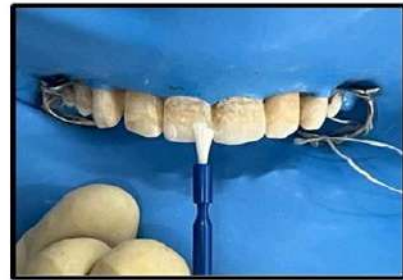Preoperative Shade Matching



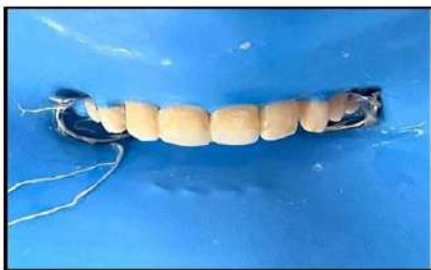Placement of Rubber dam



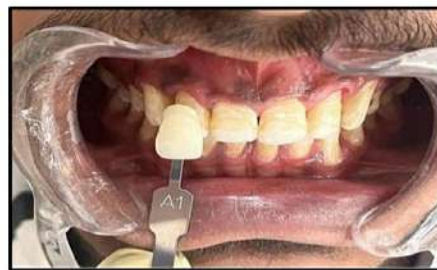Application of enamel cleaning solution



Application of Neutralizing solution

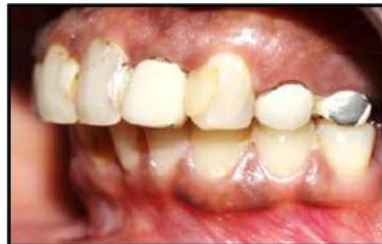
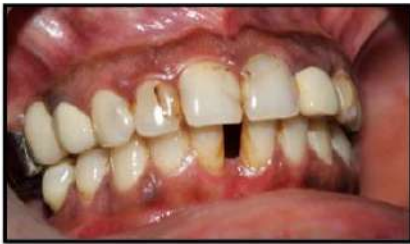
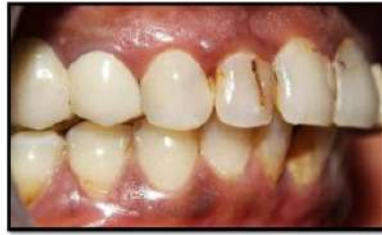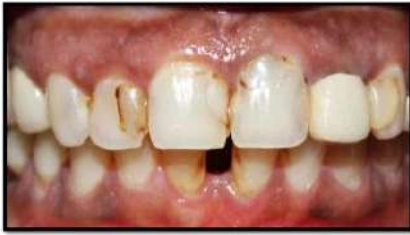Post-operative

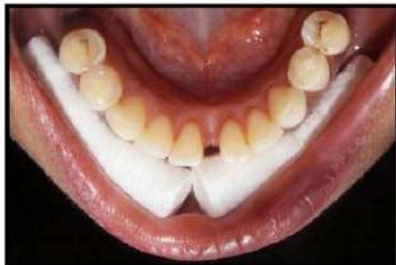
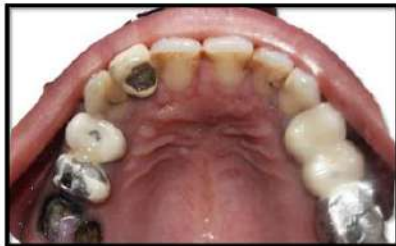
Post-operative shade matching

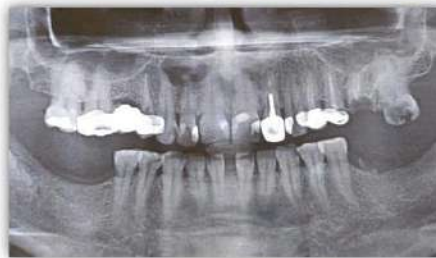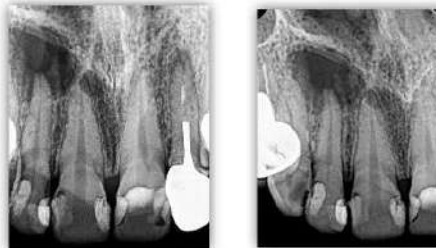Case 2: Surgical Management of Infected Radicular Cyst.



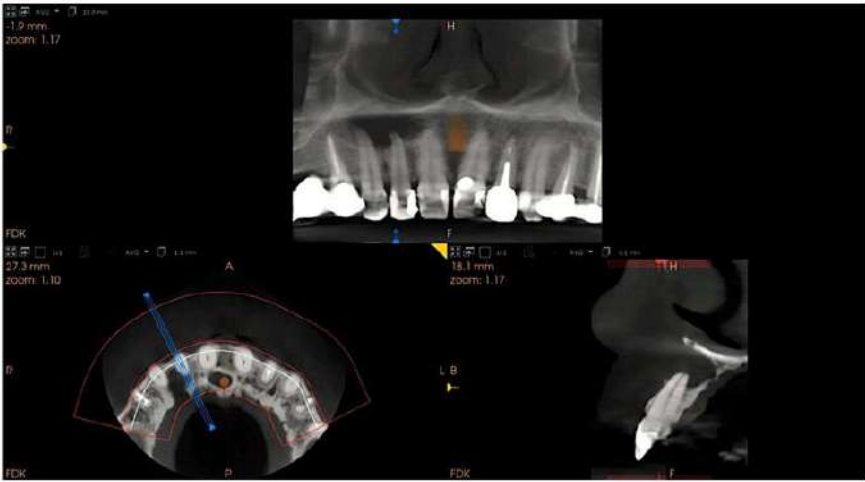PREOPERATIVE OCCLUSAL VIEW



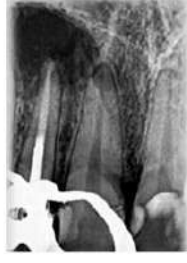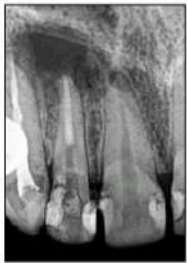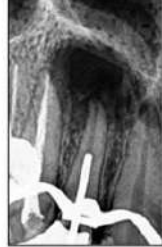
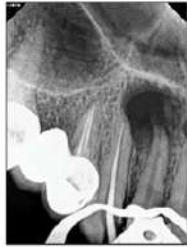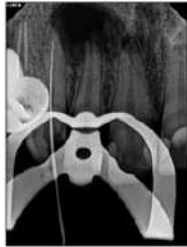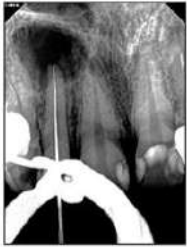PREOPERATIVE RADIOGRAPHIC IMAGES



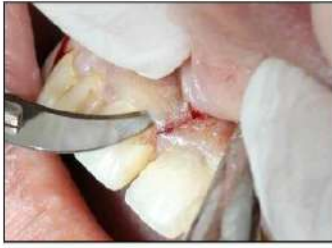PREOPERATIVE CBCT SCAN DONE



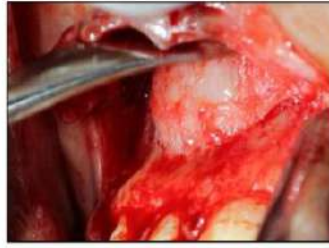7



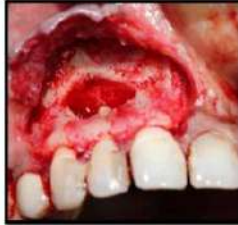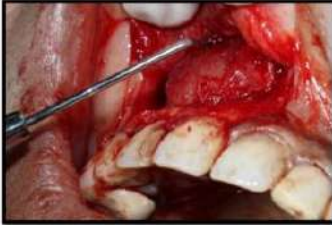8



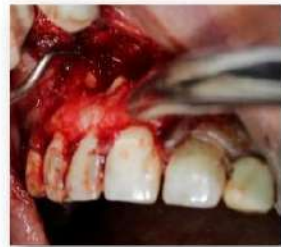SULCULAR INCISION



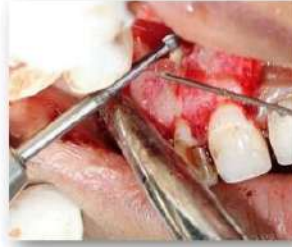FLAP REFLECTION



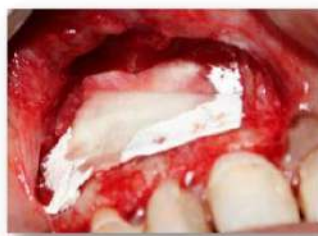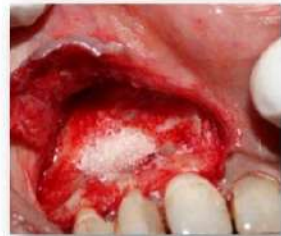Completely Enucleated Cyst Along With The Epithelial Lining

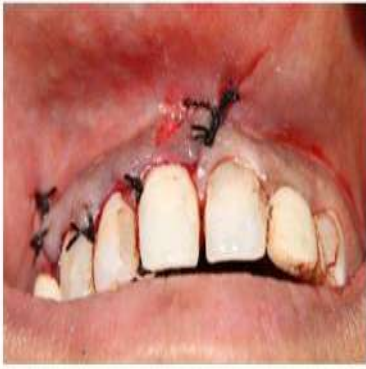

CURETTAGE OF THE CYST



APICOECTOMY

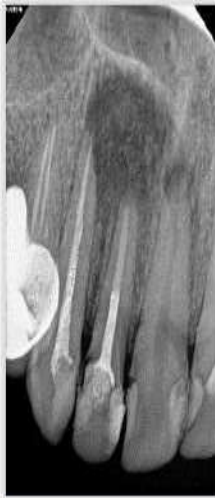



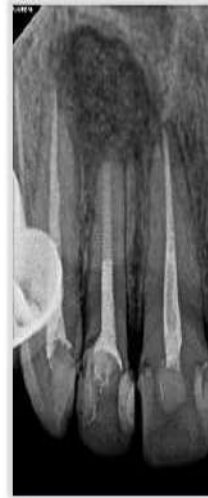Suture Placement



Enucleated specimen for Histopathological Investigations

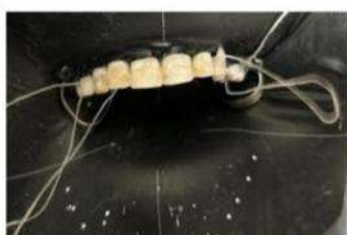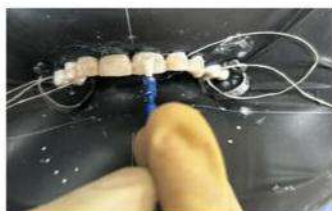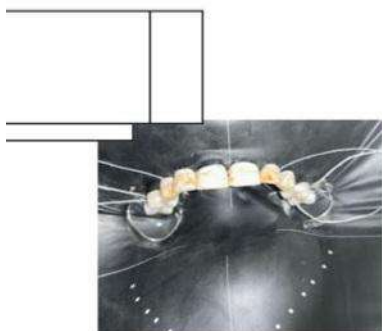


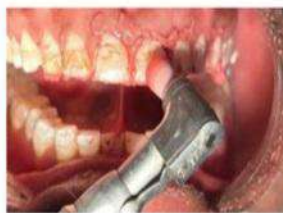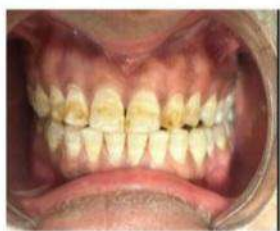Immediate post operative



1 month follow up

FEBURARY 2026

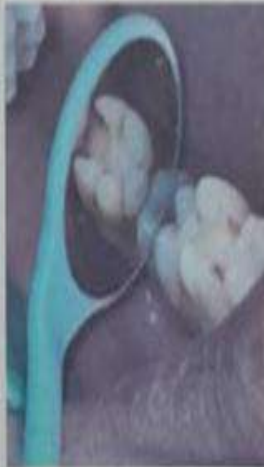

MARCH 2026

COMPOSITE INLAY



RUBBERDAM ISOLATION AND
OCCLUSAL PHOTOGRAPH



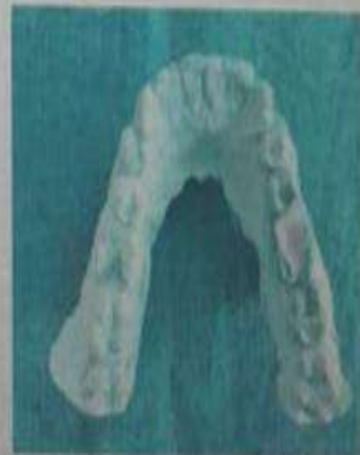INLAY CAVITY
PREPARATION



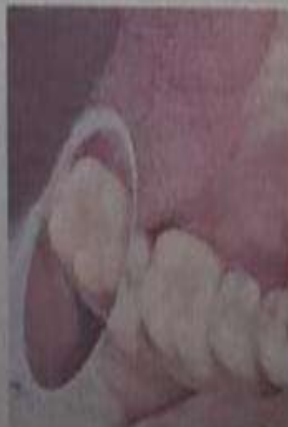IMPRESSION OF
PREPARED CAVITY



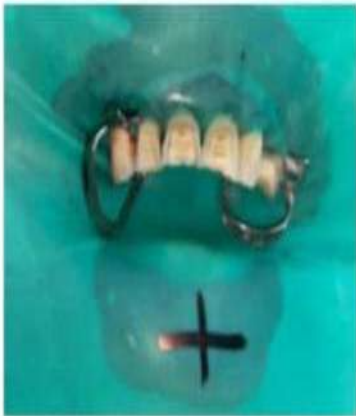MASTERCASE



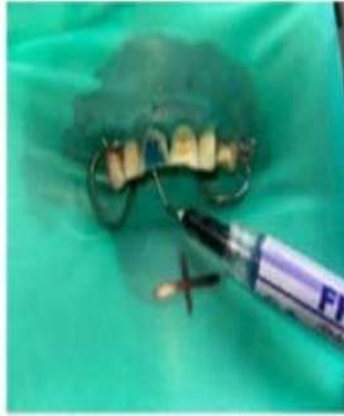COMPOSITE
PATTERN



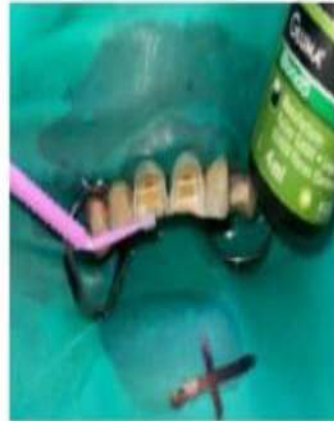COMPOSITE RESTORATION



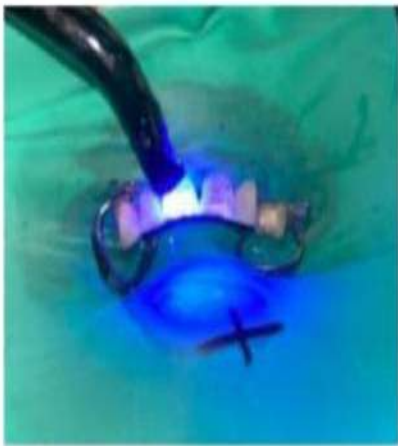APPLICATION OF RUBBER DAM



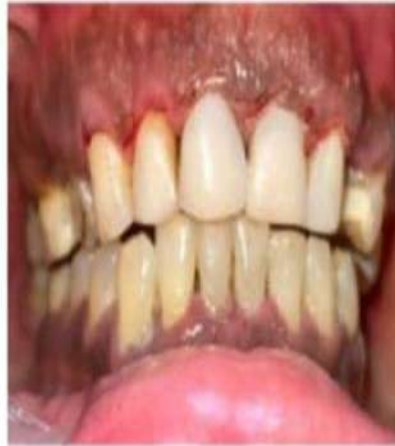APPLICATION OF ETCHANT



APPLICATION OF BONDING AGENT



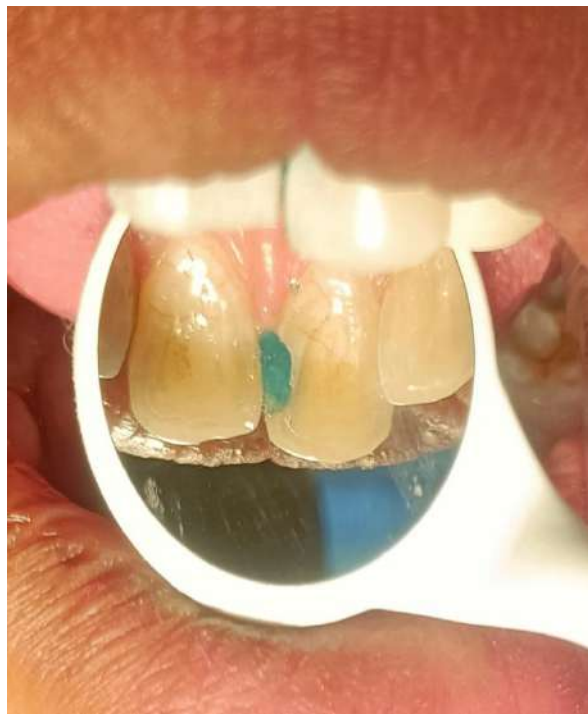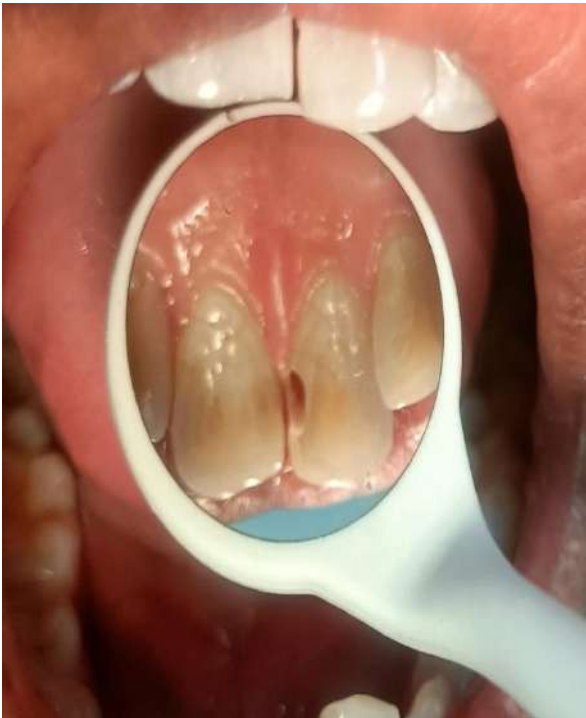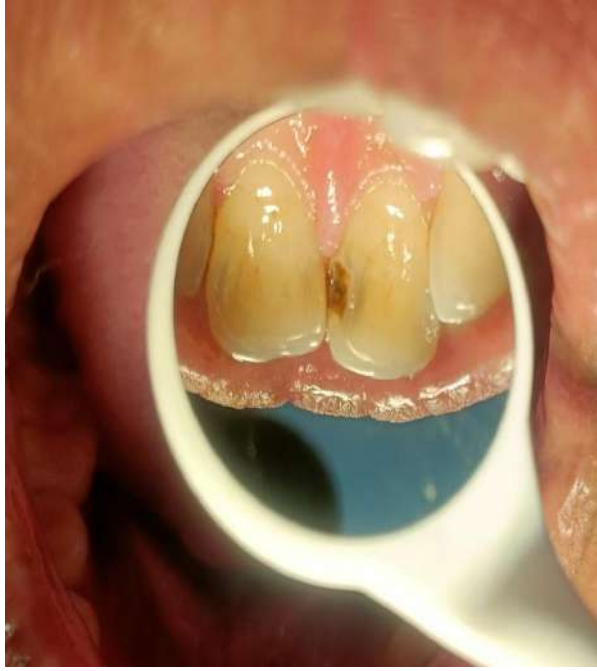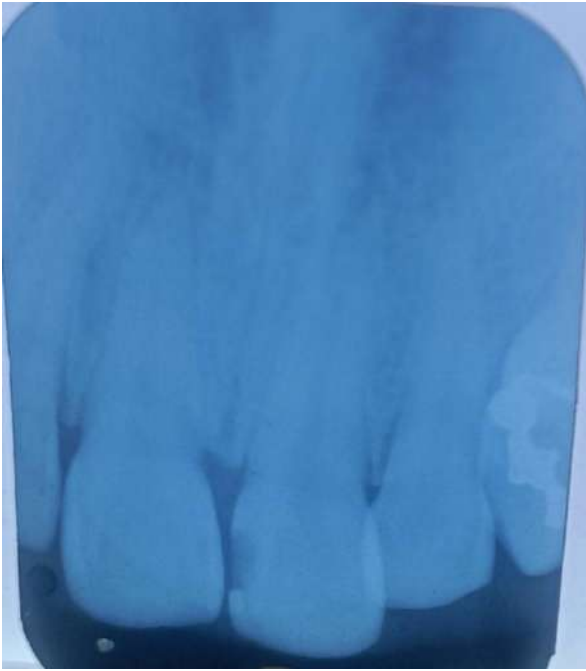CURING OF BONDING AGENT

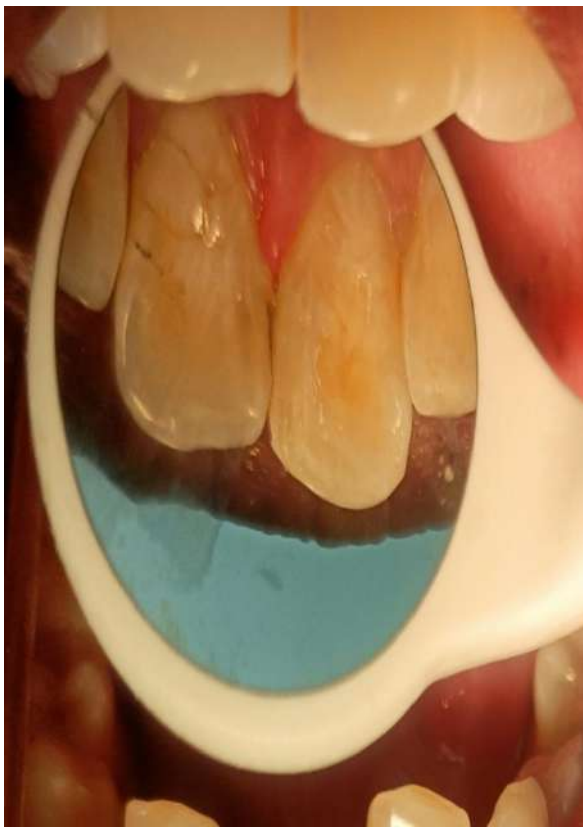
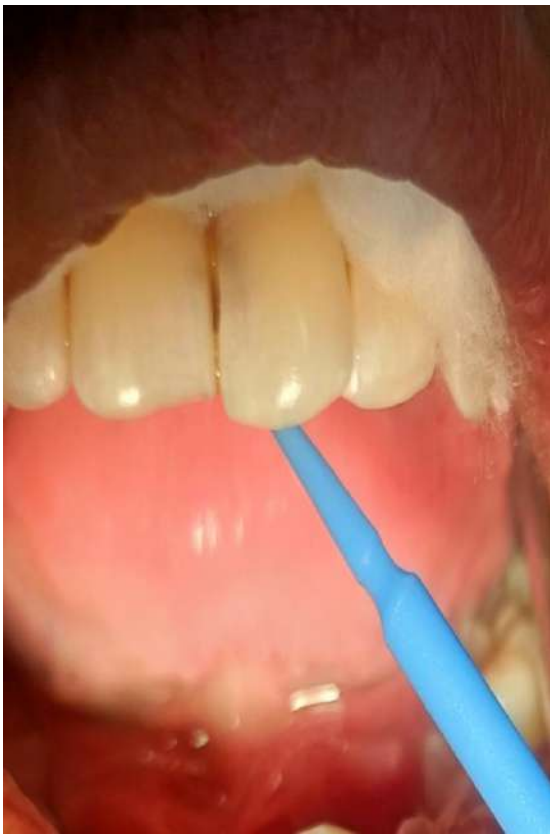
POST OPERATIVE RESULT

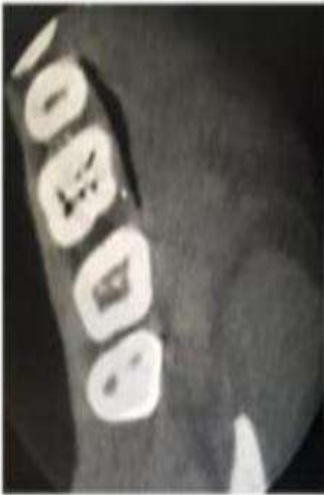APRIL 2026

ANTERIOR BUILD- UP COMPOSITE RESTORATION

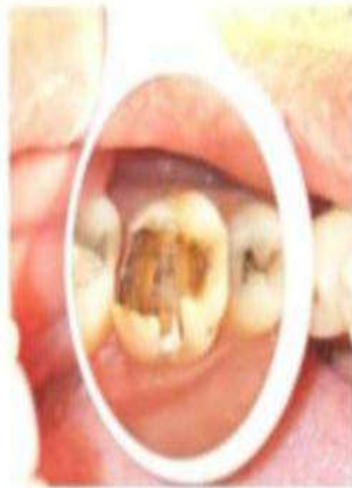



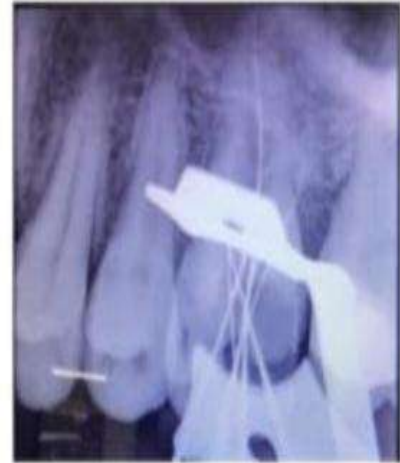CASE Of 6 CANALS in UPPER 1st MOLAR



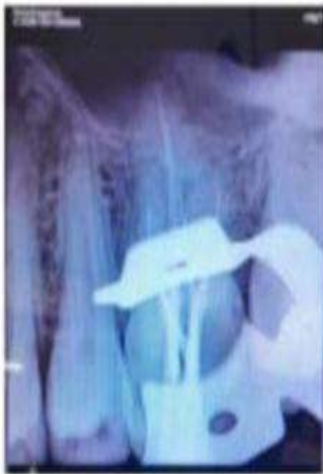CBCT (CROSSSECTIONAL)
VIEW



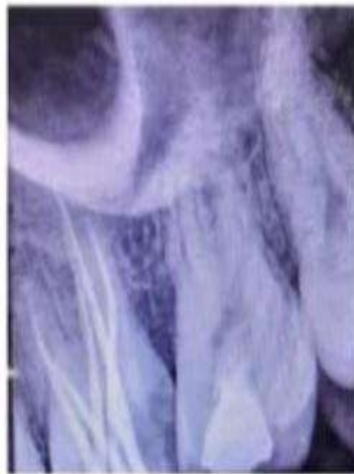CLINICALLY OCCLUSAL
VIEW



WORKING LENGTH
DETERMINATION



MASTER CONE RADIOGRAPH



OBTURATION DONE

